ACTA OPHTHALMOLOGICA 64 (1986) 113–122

Computerized enhancement of retinal nerve fiber layer

Eli Peli, Thomas R. Hedges and Bernard Schwartz

Department of Ophthalmology (Head: Bernard Schwartz),
New England Medical Center and Tufts University School of Medicine,
Boston, Massachusetts, USA

Abstract. We investigated a number of image processing techniques for enhancing the retinal nerve fiber layer (NFL) in fundus photographs taken with red-free light. Wedge-type defects within the NFL were enhanced best by contrast enhancement algorithms such as histogram modification and extremum sharpening. Narrow, slitlike NFL defects can be enhanced by directional enhancement techniques. Normal NFL features were enhanced best by high-pass filtering techniques such as homomorphic filtering and adaptive enhancement. The enhanced normal NFL may be useful in the analysis of diffuse NFL loss. All of these successful enhancements of normal and defective features indicate that enhancing fundus photographs with digital image processing techniques should facilitate early detection of optic nerve damage from glaucoma and other diseases.

Key words: nerve fiber layer – retina – computerized enhancement – fundus photography – optic nerve – digital image processing.

Since Hoyt rekindled interest in Vogt's method of observing the retinal nerve fiber layer (NFL) with red-free light (Vogt 1917; Hoyt et al. 1972a,b, 1973), there have been efforts to apply this technique to patients suffering from a variety of optic nerve disorders. Defects in the NFL appear to be an objective and sensitive indicator of optic neuropathy, and NFL observation leads to improved diagnosis and therapy of patients with optic nerve disease.

Although many preliminary clinical studies employing NFL evaluation appear promising (Hoyt & Knight 1973; Frisén & Hoyt 1974; Lundström & Frisén 1975, 1976; Sommer et al. 1977; Vannas et al. 1977; Quigley et al. 1980, 1982; Newman et al. 1982; Airaksinen & Heijl 1983; Levin et al. 1983), observation of the NFL remains difficult in many patients. The major problem is that the bright lines created by the nerve fiber bundles overlying the dark background of the choroid have poor contrast, making both observation and photography in white light difficult. Red-free light creates a darker choroidal background and improves NFL visibility. Various photographic techniques involving changes or adjustments in lighting systems, filters, films, and printing techniques have been used to improve NFL photographs (Frisén & Hoyt 1973; Gragoudas et al. 1978; Frisén 1980; Quigley & Addicks 1982; Airaksinen et al. 1982; Sommer et al. 1983a,b, 1984a; Nanba & Iwata, in press). A more quantitative approach has been taken by Lundström & Eklundh (1980), who attempted computerized microdensitometry for the evaluation of NFL loss.

Use of computerized image enhancement of NFL photographs can improve the overall visual appearance of an image and can transfer an image to a form better suited to further computer processing (Pratt 1978). We have applied several image enhancement algorithms to a variety of NFL photographs. The various algorithms are divided into two principal groups: those that enhance the NFL itself and those that enhance the NFL defects.

Material and Methods

Photography

NFL photographs are taken routinely of patients with glaucoma, ocular hypertension, and a variety of optic nerve disorders. We have experimented with a number of variations in photographic technique. We currently use the Canon CF-60Z camera and take four 30° views of the superior and inferior portions of both nasal and temporal peripapillary areas. At present we employ an SR-540, green interference, red-free filter as a contrast intensifier, although we have also found a blue 'fluorescein exciter' type filter to be useful. The camera's power unit is set at 7 or 8, depending on pupil diameter and pigmentation of the fundus. ISO 125 Plus-X film is exposed and processed in Kodak D-11 1 : 1 for 6 min (Sommer et al. 1983b). We then re-expose the negatives onto Kodak Kodalith (high contrast) film to produce positive 35-mm slides.

Data acquisition

Negatives of NFL photographs are digitized using the EYECOM video digitizer (Spatial Data Systems, Goleta, Calif.) at the Image Analysis Laboratory of the New England Medical Center. Data, sampled at a resolution of 512 × 512 pixels and at 256 gray levels, is stored on computer disks and magnetic tape. The DeAnza Corporation's (Beverly Hills, Calif.) IP-5000 system image processing unit is used to display the images. Computations involving such large numbers of data points require a fast computer with sufficient storage space; we use the VAX 11/780 (Digital Corp., Maynard, Mass.).

The image is defined in the algorithms as $F(i,j)$, where i and j are the horizontal and vertical coordinates of each picture element, respectively, and the value of $F(i,j)$ at each point represents the gray level of that point in the image.

Enhancement by high-pass filtering techniques

The NFL pattern is composed of fine striations, which contribute to the high spatial frequency content of the image. As a result, various types of high-pass filtering methods (i.e., operations that enhance the high spatial frequencies and depress the low spatial frequencies) can be used to enhance this aspect of the image (Pratt 1978). We have applied two such techniques, homomorphic filtering (Oppenheim et al. 1968) and adaptive enhancement (Peli & Lim 1982; Peli & Peli 1984). Homomorphic filtering is a global operation that processes the whole image in the same fashion. The adaptive enhancement algorithm operates locally and affects various parts of the image differently, depending on the local luminance mean.

Homomorphic filtering

Homomorphic filtering has been successfully applied to enhancement of images degraded by shadows, atmospheric haze, or clouds. The technique assumes that the degrading interference is multiplicative with the image and contains mostly low frequencies, while the features that are of interest are of high frequency. The recorded image $F(i,j)$ is defined as

$$F(i,j) = I(i,j) \cdot E(i,j),$$

were $I(i,j)$ is the non-degraded image, and $E(i,j)$ is low-pass degrading field or variable illumination.

Taking the logarithm of $F(i,j)$ yields

$$\log [F(i,j)] = \log [I(i,j)] + \log [E(i,j)].$$

This is an additive noise expression allowing successful enhancement with conventional linear high-pass filters. We have transformed the logged image into the frequency domain using the Fast Fourier Transform (FFT) and have applied a high-pass filter with a Gaussian profile. The filtered image is then transformed back to the space domain, using an FFT, and displayed on the screen.

Adaptive image enhancement

The adaptive enhancement algorithm was developed for images degraded by cloud cover or shadows (Peli & Lim 1982). The adaptive nature of the algorithm results from changing the processing parameters at every point in the image based on its local characteristics. The image $F(i,j)$ is separated into two components:

$$F(i,j) = F_L(i,j) + F_H(i,j),$$

where $F_L(i,j)$ represents the local luminance mean (low-frequency content of the image). $F_H(i,j)$, the local high-frequency content of the image, is amplified by multiplying it by $K[F_L(i,j)] > 1$, a scalar that is a function of the local luminance mean. The final local luminance mean is also modified by a non-linear function of the original local luminance mean. The two modified components are then combined to produce the final image. The main advantage of this technique over others, such as unsharp masking of photographs (a removal of low-frequency content of the film using a blurred mask) (Frisén & Hoyt 1973) and homomorphic filtering, is that rather than modifying the whole image uniformly, it modifies local contrast as a function of local luminance mean.

This allows for more contrast enhancement of the NFL (intermediate luminance mean) and less for blood vessels (low luminance mean) and the optic disc (high luminance mean). The control of the local luminance mean enables the operator to decide whether low-frequency content will be maintained over the whole image or whether extreme brightness changes across the image will be reduced.

Directional enhancement of the NFL

In any small area of an NFL photograph the fibers can be approximated by a series of parallel lines. The direction of these bundles varies only slightly when one moves from one area to the next. A number of directional filters that enhance only in a specific direction have been decribed (Pratt 1978). Most filters are directional derivatives or edge detectors; thus, they tend to respond better to an edge than to a series of lines. We used a fan-type (pie-slice shaped) filter in the Fourier domain (Moik 1980; Peli & Verly 1983). A series of parallel lines in the space (image) domain results in peaks along the orthogonal direction in the Fourier (frequency) domain. Amplifying these peaks should enhance the parallel lines. An inverse filter of the fan configuration has been shown to be very effective in differentially removing series of parallel lines from images (Peli & Verly 1983). We have applied such a filter with a rectangular profile to enhance the NFL in a small area. The proper direction to be enhanced can be fed interactively by the experimenter and can be detected automatically in the Fourier domain. Such detection requires prior non-linear enhancement of the NFL (such as adaptive enhancement) to obtain higher energy in the fiber direction. When moving to a neighboring area, the search for the proper direction can be narrowed based on a priori knowledge of the general pattern of the NFL and the direction of neighboring enhanced areas.

Enhancement of focal NFL defects

Focal slit- and wedge-type NFL defects appear as dark grooves with diminished NFL striations and brightness. The contrast of these changes is often low, because the image usually does not span the whole dynamic range of the film. For the human eye to see subtle changes in brightness, the brightness range of the image should be adapted to the human subjective brightness range. Such adaptation is commonly achieved by a gray-scale transformation (Moik 1980). We have applied two such transformations: histogram modification techniques (Hall 1974) and extremum sharpening (Lester et al. 1980). Histogram modifications are global techniques, which operate on the whole image at once, while extremum sharpening is a local operator that enhances contrast at local areas within the range of the original image.

Histogram modification

Luminance, or gray-level, histograms of NFL photographs are highly skewed toward darker levels as a result of the red-free filter in the camera. Contrast enhancement of such images may be obtained by a gray-scale transformation, which resutls in a picture of a specified distribution of gray levels. Histogram equalization is one such rescaling method: it produces an image for which the histogram is uniform (flat) (Hall 1974). Histogram equalization enhances the contrast because pixels in densely populated regions of the gray scale are forced to occupy a larger range of gray levels. As a result, these regions are stretched.

Histogram hyperbolization is a technique in which the resultant image has a hyperbolic gray scale probability density (Pratt 1978). With this technique it is assumed that the final image following the logarithmic response of retinal photoreceptors will have a uniform histogram. In practice this technique results in a slightly darker image with less 'blooming' of bright areas. The transfer functions for both histogram equalization and histogram hyperbolization have been given by Pratt (1978).

Extremum sharpening

Extremum sharpening is a local operator used to deblur or sharpen images and has been applied successfully in processing images of blood cells (Lester et al. 1980). For a window around a point (i,j), the operator assigns to that central point the value of the extreme gray level in the window that is closest to the gray level of the point (i,j). The algorithm is useful to improve image quality both for human observation and later processing. If it is applied recursively it also tends to consolidate isodense regions and mask underlying texture (like the median-smoothing algorithm). This recursive application is useful when one tries to delineate the extent of slit- or wedge-type NFL damage for quantification and longitudinal comparison. The algorithm is characterized also by fairly fast con-

A

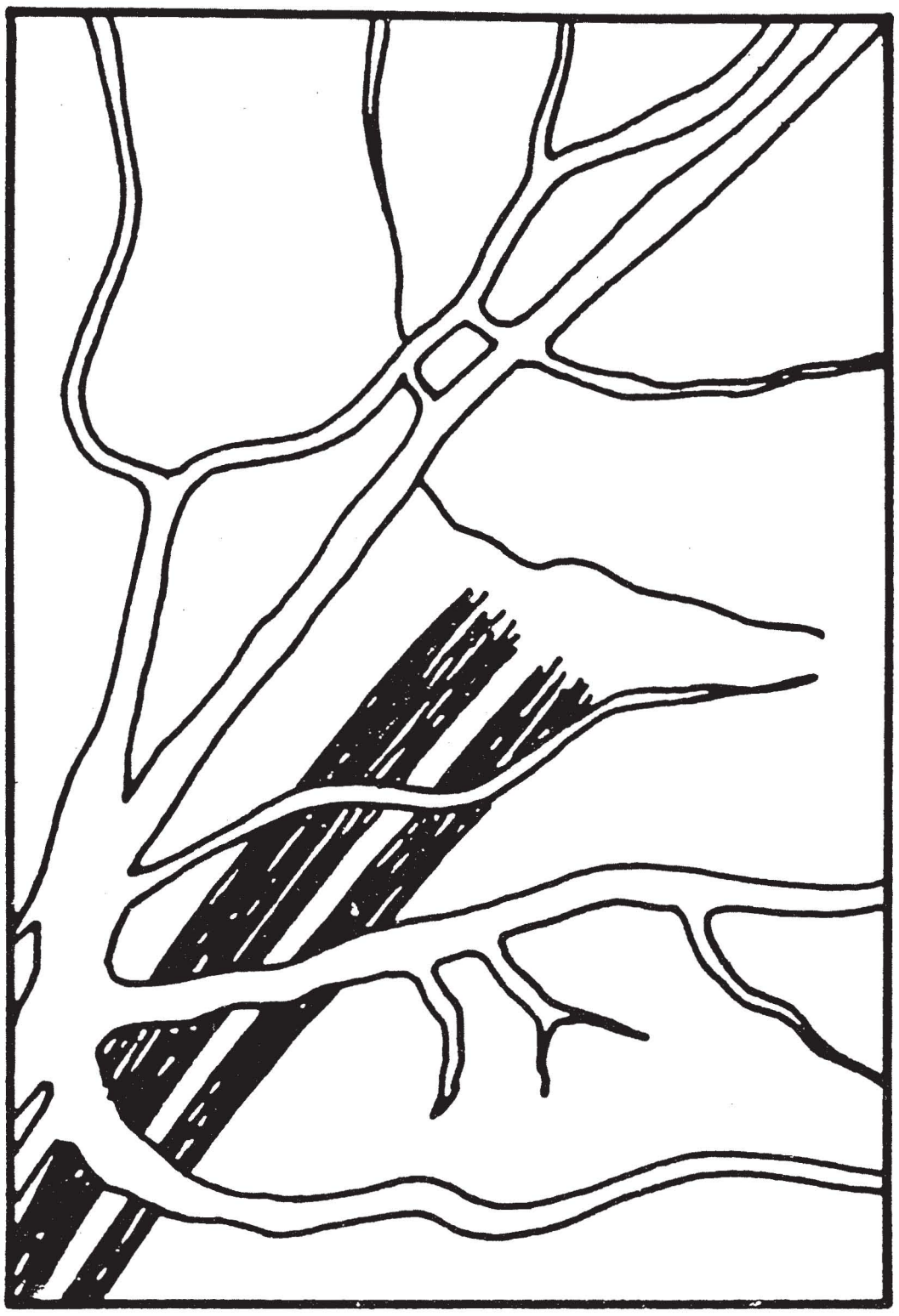
B

vergence to a stable state in recursive application. Typical application of the algorithm for such delineation of NFL damage will include median smoothing followed by recursive extremum application and a final, smaller window and median filtering to smooth the borders of the enhanced damaged area.

Results

Fig. 1 demonstrates enhancement of focal NFL damage in a glaucoma patient with two wide wedge defects (schematically illustrated in Fig. 1B). Histogram equalization, shown in Fig. 1C, results in enhancement of the wedge defect. The result of 4 iterations of the extremum sharpening algorithm is shown in Fig. 1D. The wedge defects are well delineated with sharp, smooth borders and even luminance.

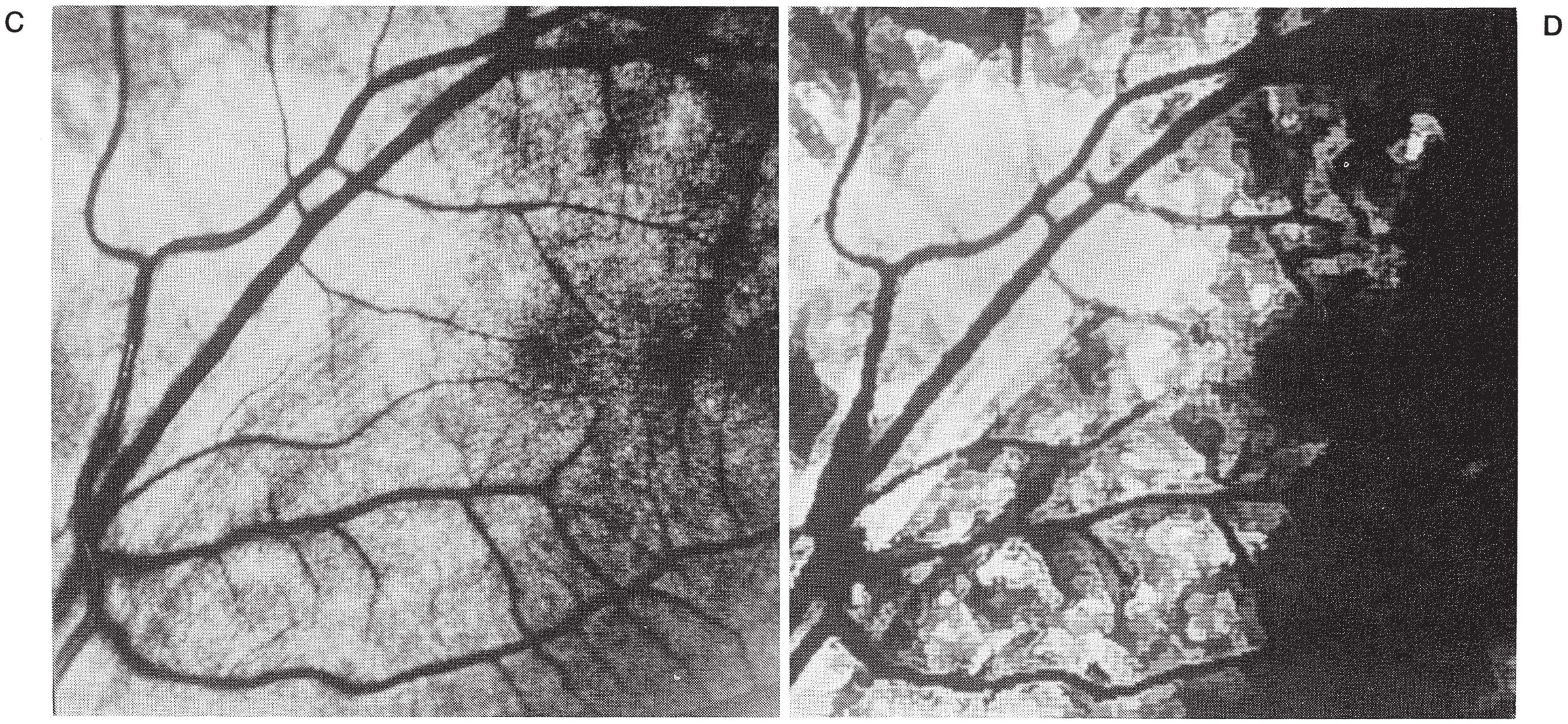

Fig. 1.
Enhancement of wedge-type defects in the NFL. A. Original red-free photograph of superior temporal retina (OS) of a glaucoma patient showing 2 wedge-type defects. B. Schematic illustration of the wedge defects in 1A. C. Result of histogram equalization of image in 1A. The defects are seen with higher contrast and are easier to detect. D. Result of 4 iterations of the extremum sharpening algorithm on the image in Fig. 1A. The defects are enhanced; their borders are sharpened and well delineated.

Fig. 2 shows enhancement of details of NFL structure in a patient with a large central scotoma resulting from Leber's hereditary optic neuropathy. The original image is presented in Fig. 2A. The same image, enhanced with the adaptive enhancement algorithm, is shown in Fig. 2B. Normal NFL striations are clearly enhanced outside the central arcade, where there is no NFL loss, whereas some residual striations can be seen inside the arcade in the large area of diffuse loss. These striations are difficult to detect in the original image.

Fig. 3A shows multiple narrow, slitlike defects in a patient with a chiasmal glioma. In such cases techniques to enhance NFL details will also enhance the narrow, slitlike defects. Results of adaptive and homomorphic filtering are shown in Figs. 3B and 3C, respectively. In both cases NFL defects can be noted more easily within the vascular arcade and centrally in the enhanced images.

Fig. 3D demonstrates the effect of applying directional enhancement within small windows (64 × 64 and 32 × 32) of the original image. Vessels perpendicular to the NFL are suppressed within these windows.

Discussion

Many investigators have devised methods to improve the quality of NFL photographs. Shorter wave length filters give better contrast than longer wave length filters (Airaksinen et al. 1982; Sommer et al. 1983b), although shorter wave length light suffers from more scattering in hazy media. The best compromise between these opposing qualities is use of a 505-nm filter (Gragoudas et al. 1978). Linear polarizers were reported to be equal in value to red-free filtration with heavily pigmented fundi (Quigley & Addicks 1982); however, they may not be as useful in eyes with lighter pigmentation. Crossed linear polarizers appear to be advantageous (Sommer et al. 1984), although only preliminary results have been reported. The unsharp masking technique of photographic printing, which enhances edges through multiple photographic development phases, improves NFL

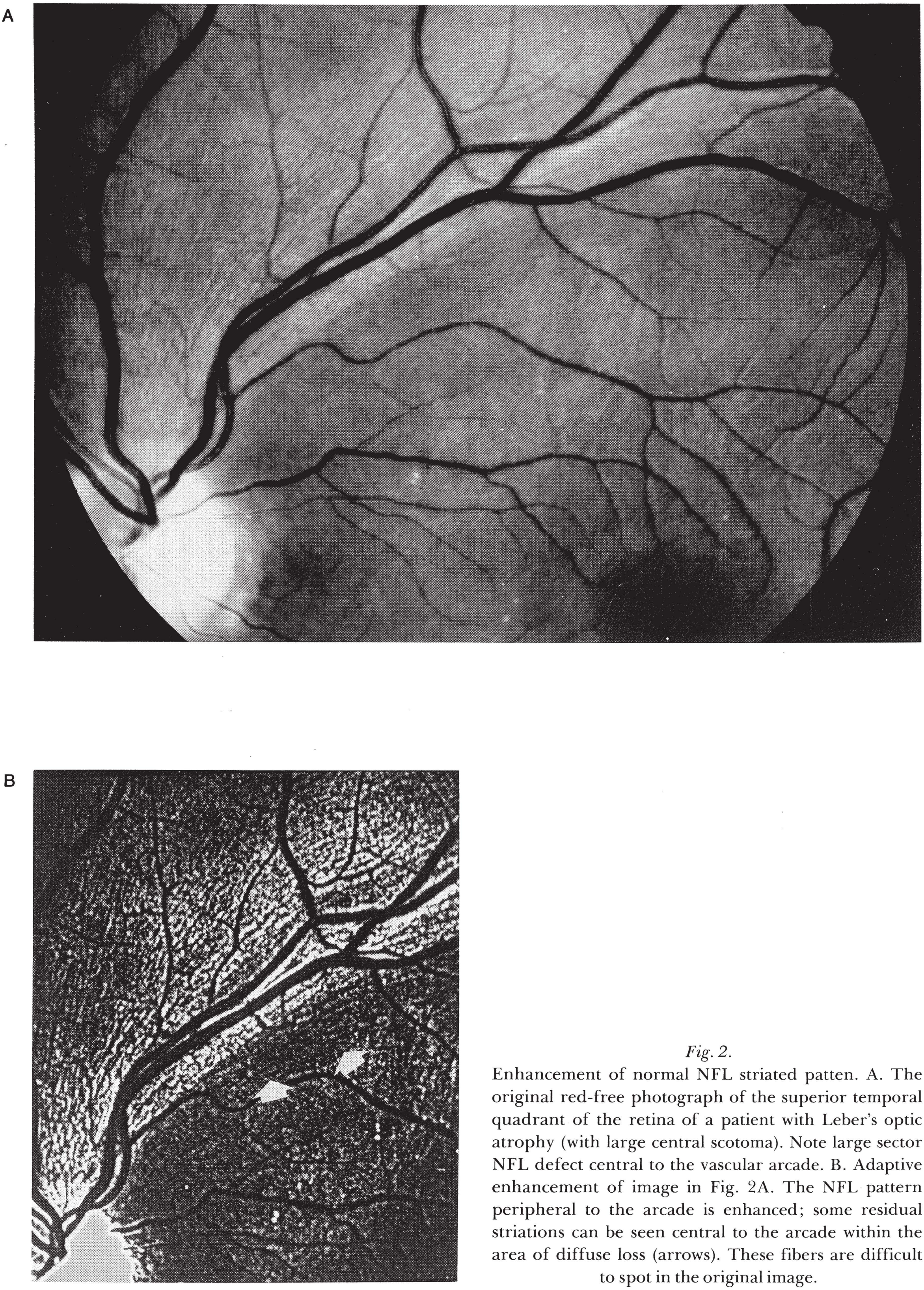

Fig. 2.
Enhancement of normal NFL striated patten. A. The original red-free photograph of the superior temporal quadrant of the retina of a patient with Leber's optic atrophy (with large central scotoma). Note large sector NFL defect central to the vascular arcade. B. Adaptive enhancement of image in Fig. 2A. The NFL pattern peripheral to the arcade is enhanced; some residual striations can be seen central to the arcade within the area of diffuse loss (arrows). These fibers are difficult to spot in the original image.

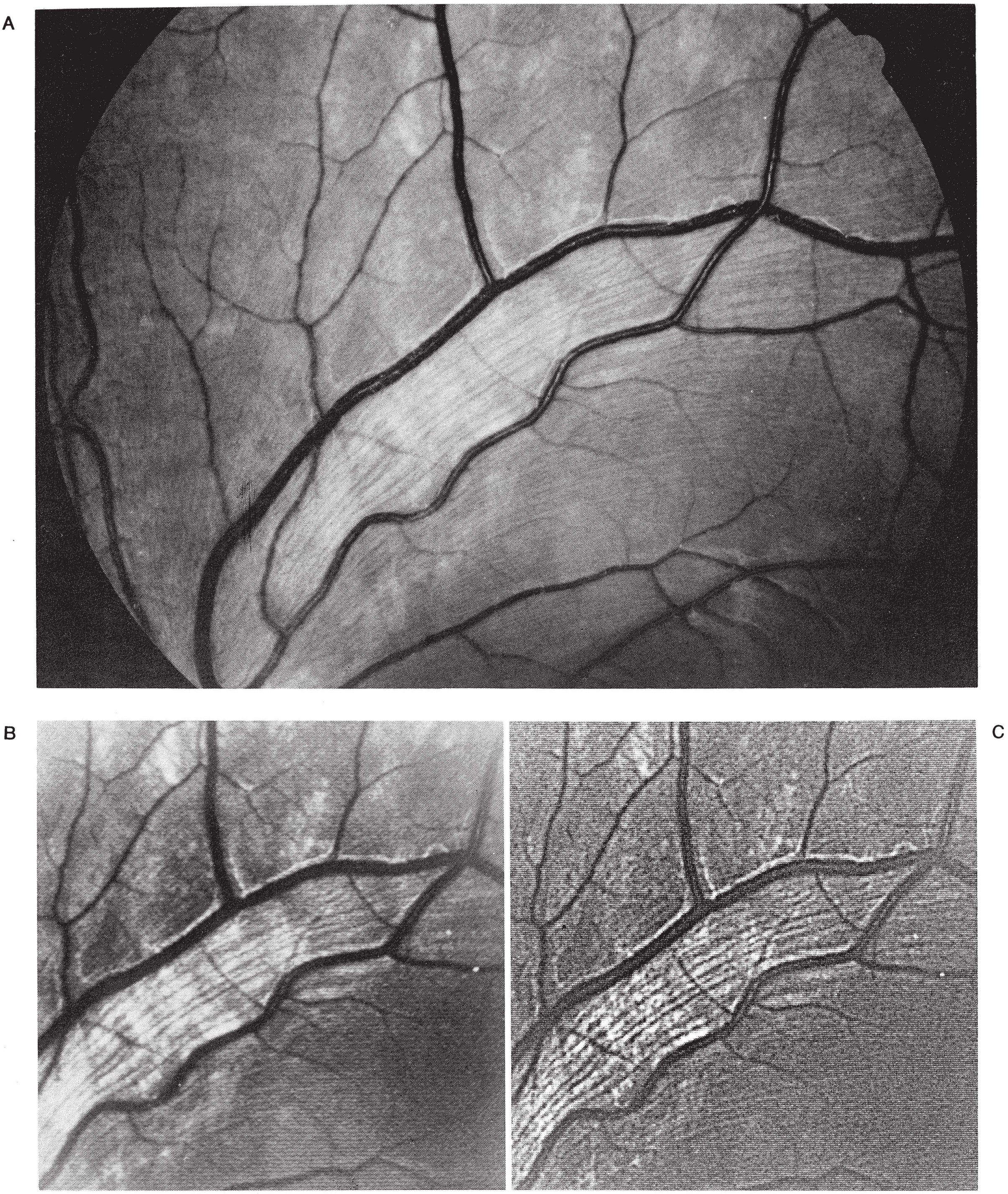

Fig. 3.

Enhancement of narrow, slitlike defects and normal NFL pattern. A. Original red-free photograph of patient with chiasmal glioma. Multiple slitlike defects can be seen within the arcade. B. Result of homomorphic filtering of image in Fig. 3A. C. Result of adaptive enhancement of image in 3A. D. Directional enhancement in two small windows superimposed on the original image. In all the enhanced images the slitlike defects within the arcade are enhanced, and similar defects central to the arcade become apparent as well.

D

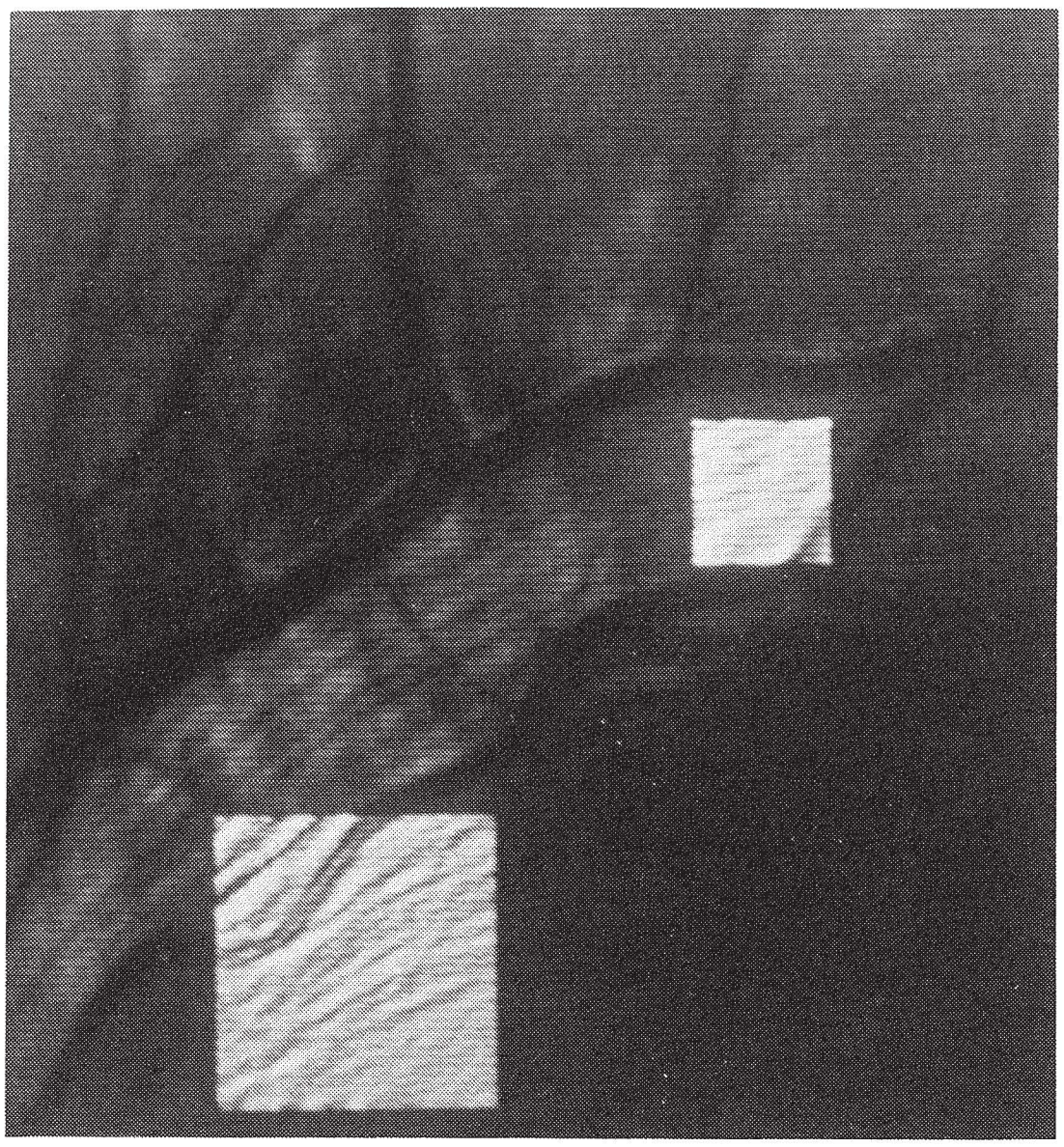

References

Airaksinen P J, Nieminen H & Mustonen E (1982): Retinal nerve fibre layer photography with a wide angle fundus camera. Acta Ophthalmol (Copenh) 60: 362–368.

Airaksinen P J & Heijl A (1983): Visual field and retinal nerve fiber layer in early glaucoma after optic disc hemorrhage. Acta Ophthalmol (Copenh) 61: 186–194.

Bille J & Katz B (1984): A digitized laser scanning fundus camera. Invest Ophthalmol Vis Sci 25. Suppl: 252.

Frisén L & Hoyt W F (1973): Unsharp masking in fundus photography. Invest Ophthalmol 12: 461–464.

Frisén L & Hoyt W F (1974): Insidious atrophy of retinal nerve fibers in multiple sclerosis: funduscopic identification in patients with and without visual complaints. Arch Ophthalmol 92: 91–97.

Frisén L (1980): Photography of the retinal nerve fibre layer; an optimised procedure. Br J Ophthalmol 64: 641–650.

Gragoudas E, Delori F & Francisco R (1978): Monochromatic fundus photography. 5th Congr Eur Soc Ophthalmol, Hamburg, 1976, pp 50–55. Ferdinand Enke Verlag, Stuttgart.

Hall E L (1974): Almost uniform distribution for computer image enhancement. IEEE Transactions, Computers, C-23, 2: 207–208.

Hoyt W F, Schlicke B & Eckelhoff R J (1972a): Fundoscopic appearance of a nerve-fibre bundle defect. Br J Ophthalmol 56: 577–583.

Hoyt W F, Rios-Montenegro E N, Behrens M M & Eckelhoff R J (1972b): Homonymous hemioptic hypoplasia. Funduscopic features in standard and red-free illumination in three patients with congenital hemiplegia. Br J Ophthalmol 56: 537–545.

Hoyt W F, Frisén L & Newman N M (1973): Fundoscopy of nerve fiber layer defects in glaucoma. Invest Ophthalmol 12: 814–829.

Hoyt W F & Knight C L (1973): Comparison of congenital disc blurring and incipient papilledema in red-free light – a photographic study. Invest Ophthalmol 12: 241–247.

Lester J M, Brenner J F & Selles W D (1980): Local transforms for biomedical image analysis. Computer Graphics and Image Processing 13: 17–30.

Levin P S, Newman S A, Quigley H A & Miller N R (1983): A clinicopathologic study of optic neuropathies associated with intracranial mass lesions with quantification of remaining axons. Am J Ophthalmol 95: 295–306.

Lundström M & Frisén L (1975): Evolution of descending optic atrophy: a case report. Acta Ophthalmol (Copenh) 53: 738–746.

Lundström M & Frisén L (1976): Atrophy of optic nerve fibres in compression of the chiasm. Acta Ophthalmol (Copenh) 54: 623–640.

Lundström M & Eklundh J O (1980): Computer densitometry of retinal nerve fibre atrophy, a pilot study. Acta Ophthalmol (Copenh) 58: 639–644.

Mainster M A, Timberlake G T, Webb R H & Hughes G W (1982): Scanning laser ophthalmoscopy: clinical applications. Ophthalmology 89: 852–859.

Moik J G (1980): Digital processing of remotely sensed images. National Aeronautics and Space Administration, Washington, D.C.

Mustonen E & Nieminen H (1982): Optic disc drusen – a photographic study. II. Retinal nerve fibre layer photography. Acta Ophthalmol (Copenh) 60: 859–872.

Nanba K & Iwata K (in press): Visualization and documentation of retinal nerve fiber layer defects (RNFL-D). I. Spectral characteristics of RNFL-D. Jpn Clin Ophthalmol.

Nathan R (1970): Spatial frequency filtering. In- Lipkin B S & Rosenfeld A (eds). Picture Processing and Psychopictorics. p 151. Academic Press, London.

Newman N M, Tornambe P E & Corbett J J (1982): Ophthalmoscopy of the retinal nerve fiber layer: use in detection of neurologic disease. Arch Neurol 39: 226–233.

Oppenheim A V, Schafer R W & Stockham T G (1968): Nonlinear filtering of multiplied and convolved signals. Proc IEEE 156: 1264–1291.

Peli T & Lim J S (1982): Adaptive filtering for image enhancement. Optical Engineering 21: 108–112.

Peli T & Verly J G (1983): Digital line-artifact removal. Optical Engineering 479–484.

Peli E & Peli T (1984): Image enhancement for the visually impaired. Optical Engineering 23: 47–51.

Pratt W K (1978): Image Enhancement and Restoration in Digital Image Processing, pp 307–470. John Wiley & Sons, New York.

Quigley H A, Miller N R & George T (1980): Clinical evaluation of nerve fiber layer atrophy as an indicator of glaucomatous optic nerve damage. Arch Ophthalmol 98: 1564–1571.

Quigley H A & Addicks E M (1982): Quantitative studies of retinal nerve fiber layer defects. Arch Ophthalmol 100: 807–814.

Quigley H A & Addicks E M & Green W R (1982): Optic nerve damage in human glaucoma III. Quantitative correlation of nerve fiber loss and visual field defect in glaucoma, ischemic neuropathy, papilledema, and toxic neuropathy. Arch Ophthalmol 100: 135–146.

Sommer A, Miller N R, Pollack I, Maumenee A E & George T (1977): The nerve fiber layer in the diagnosis of glaucoma. Arch Ophthalmol 95: 2149–2156.

Sommer A, D'Anna S, Kues H & Arkell S (1983a): Photographic enhancement of the nerve fiber layer. Invest Ophthalmol Vis Sci 24. Suppl: 79.

Sommer A, D'Anna S A, Kues H A & George T (1983b): High-resolution photography of the retinal nerve fiber layer. Am J Ophthalmol 96: 535–539.

Sommer A, Kues H A, D'Anna S A, Arkell S, Robin A & Quigley H A (1984a): Cross-polarization photography of the nerve fiber layer. Arch Ophthalmol 102: 864–869.

Sommer A, Quigley H, Miller N, Robin A & Arkell S (1984b): Prospective assessment of the nerve fiber layer in glaucoma. Invest Ophthalmol Vis Sci 25: Suppl 193.

Vannas A, Raitta C & Lemberg S (1977): Photography of the nerve fiber layer in retinal disturbances. Acta Ophthalmol (Copenh) 55: 79–87.

Vogt A (1917): Die Nervenfaserstreifung der menschlichen Netzhaut mit besonderer Berücksichtigung der Differentialdiagnose gegenüber pathologischen streifenformigen Reflexen (praretinalen Faltelungen). Klin Monatsbl Augenheilkd 58: 399–411.

Received on August 29th, 1985.

Author's address:

Eli Peli, M.Sc., O.D., Department of Ophthalmology,
Tufts-New England Medical Center, Box 450,
171 Harrison Avenue, Boston, Massachusetts,
02111 USA.